

# dopplex ABILITY

## PVR Application Note

### What is PVR?

**Pulse Volume Recording** (PVR) or **Volume Plethysmography** is a non-invasive test that evaluates the blood flow in the lower extremity. PVR is a functional test and does not examine specific blood vessels, but assesses the sum of all blood flow in the examined limb. It can be used as an adjunct to the Ankle Brachial Index (ABI), can aid in the detection of Peripheral Arterial Disease (PAD) and is now one of the recognized second level assessment tools for patients with suspected PAD (ESC, 2011).

The Dopplex Ability measures the ABI and produces PVR waveforms from both ankles. This application note aims to explain these waveforms and how to interpret them.

### What are the indications for PVR?

Pulse volume recording can be undertaken for the following reasons:

- As a preliminary test to evaluate whether a patient's symptoms are related to poor blood circulation in the legs. If a patient has vague or non-specific symptoms of leg pain and it is not evident whether the symptoms are due to poor arterial circulation, then a PVR can help.
- As an adjunct to ABIs and an alternative to Doppler waveforms. Although PVR does not replace Doppler waveforms, it has been shown to have a high level of agreement.  
The PVR waveforms are very useful in patients with diabetes where the ABI may be raised into the normal range due to calcification in the blood vessels, causing results to be misleading or unclear.
- As a surveillance test to follow patients in a non-invasive way after vascular procedures or to follow a particular patient's disease process when no immediate intervention is needed.

### How is PVR performed?

PVR's utilize the principle of **plethysmography**. A cuff is placed snugly around the ankle and inflated to about 45mmHg. As the arterial blood flow moves underneath the cuff through arteries, branches and small vessels, momentary volumetric changes in the limb segment are converted into pulsatile pressure changes within the air filled cuff bladder on the ankle. A pressure transducer within the Dopplex Ability unit converts these small pressure changes into a small electrical signal which is amplified and displayed as a waveform plotted against time, Fig1.

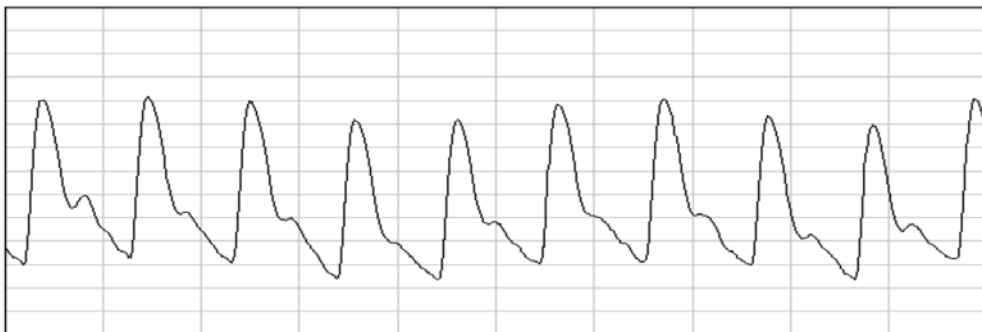


Fig 1. A normal PVR having a sharp systolic peak with prominent diastolic notch.

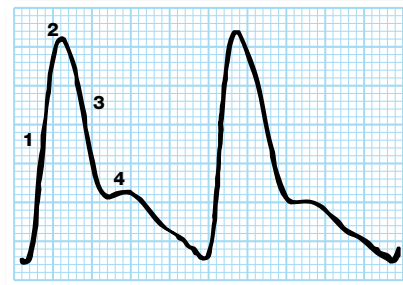
## PVR Waveform Interpretation

The interpretation of the PVR waveforms is usually undertaken by manually comparing them to the previously established four level grading system of Rumwell and McPharlin (1998). The presence of either moderate or severe abnormality in the PVR waveforms reflects significant disease at the level of the cuff. If the amplitude of the waveform is slightly reduced but there are no changes in the contour i.e. a dicrotic notch is present, the findings are likely to be insignificant.

### Normal PVR waveforms

The normal waveform has the following distinct features:

- 1) Brisk systolic upslope
- 2) Sharp systolic peak
- 3) Gradual downslope
- 4) Dicrotic notch (reflective wave) during diastole



### Abnormal PVR waveforms

The PVR waveform shape changes with the level of PAD proximal to the ankle. These include:

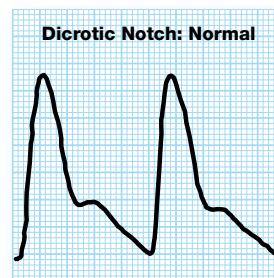
- Decrease in the rise of the upslope
- Rounding and delay in the pulse crest
- Decreased rate of fall of the downslope
- Absence of the reflected diastolic wave

The reflected diastolic wave (dicrotic notch) is of particular diagnostic significance as it disappears in the presence of PAD.

The PVR waveforms can be placed into four grades:

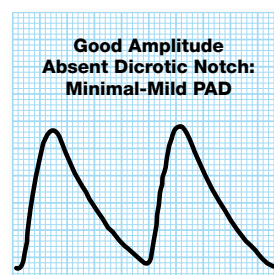
#### Grade A: Normal

Sharp systolic peak with prominent dicrotic notch



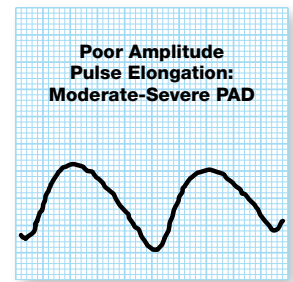
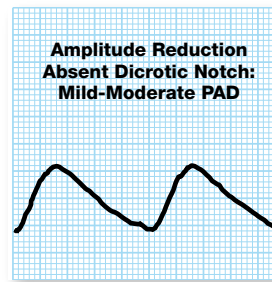
#### Grade B: Mildly Abnormal

Sharp peak, absent dicrotic notch; downslope is bowed away from baseline



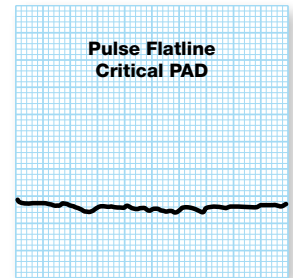
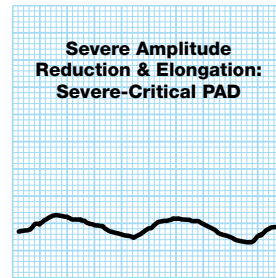
### Grade C: Moderately Abnormal

Flattened systolic peak, upslope and downslope time decreased and nearly equal, absent dicrotic notch.



### Grade D: Severely Abnormal

Low amplitude or absent pulse wave with equal upslope and downslope time

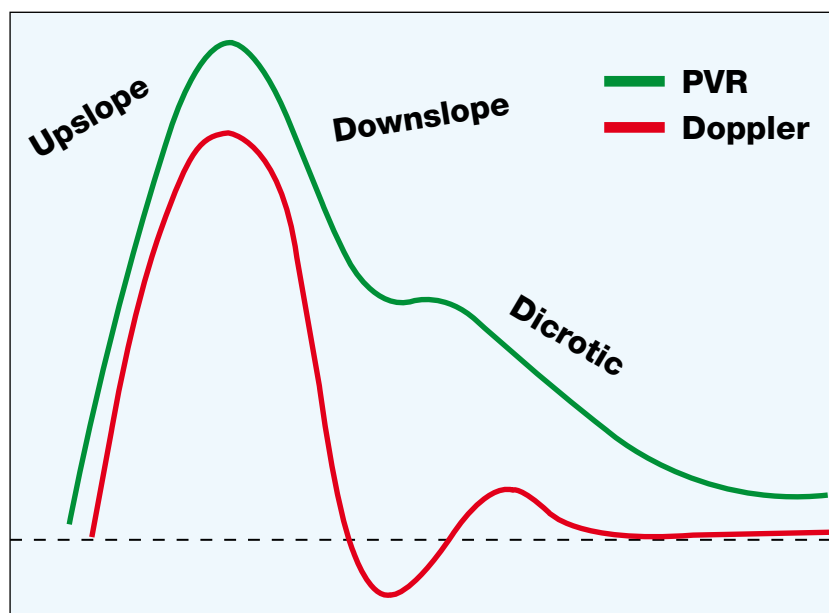


### Relationship to Doppler Waveforms

The PVR waveform is similar to an Arterial PPG waveform and does not have a baseline or zero line, unlike a Doppler blood flow waveform. Therefore the most important aspects to the waveform are its shape and height.

Lewis et al (2010) has shown that in 205 subjects, the PVR waveforms had a high level of agreement (92%) with colour spectral Doppler waveforms.

The following waveform shows the relationship between a Doppler and a PVR waveform:



The following illustrations show the type of PVR waveforms from the ankles compared to Doppler waveforms from the Posterior Tibial vessels and how they vary with different levels of PAD.

Fig 3: Normal Triphasic Doppler waveforms, pressures and ABI's (shown in brackets) from both legs and normal PVR's (grade A).

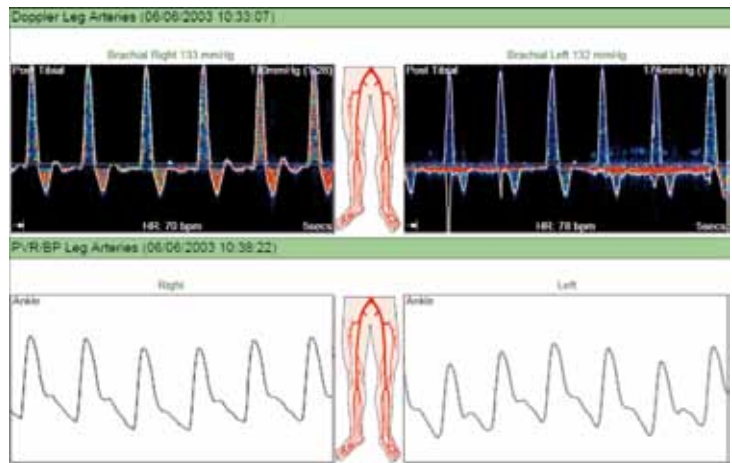


Fig 4: Right leg has normal flow, pressure and ABI with normal (grade A) PVR. Left leg has moderate PAD with monophasic Doppler waveform, low pressure and ABI, and poor, low amplitude PVR waveform (Grade D)

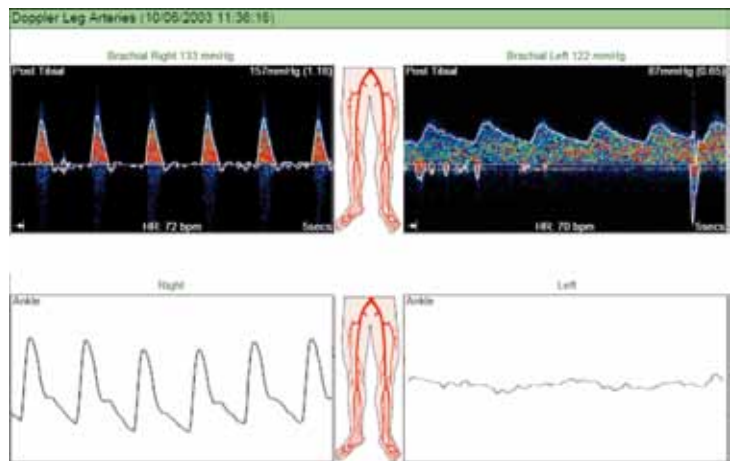
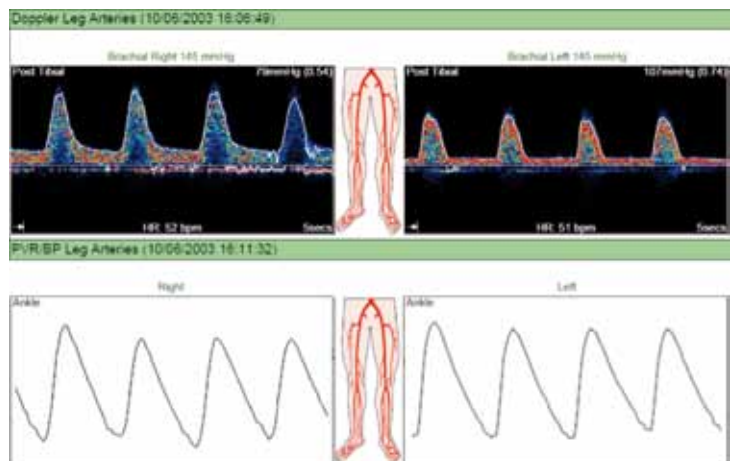


Fig 5: Both legs have moderate PAD with monophasic Doppler waveforms, low pressures and ABIs and abnormal PVR's (grade B-C).



**References:** Lewis J E A and Owens D R (2010) The Pulse Volume Recorder as a Measure of Peripheral Vascular Status in People with Diabetes Mellitus Vol 12, 1: 75-80.  
 Rumwell C, McPharlin M: Arterial Evaluation. Vascular Technology. Davis, CA: University of California, Davis, 1998: 60-69.  
 ESC Guidelines on the diagnosis and treatment of peripheral artery diseases (2011). The Task Force on the Diagnosis and Treatment of Peripheral Artery Diseases of the European Society of Cardiology (ESC). European Heart Journal. doi:10.1093/eurheartj/ehr211  
**Acknowledgements:** Dr Jane Lewis, Clinical Specialist and Research Podiatrist, Cardiff.

771158-1